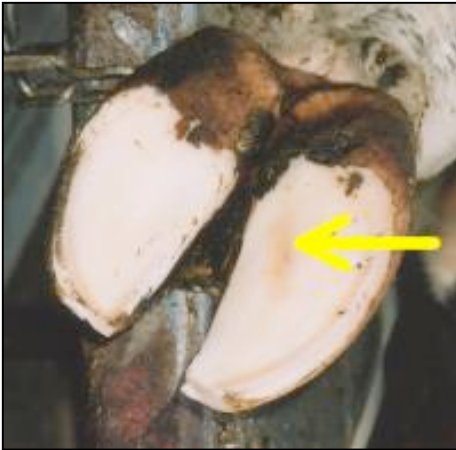

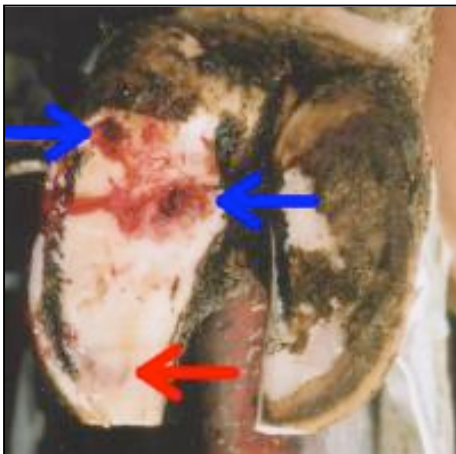
Laminitis in Dairy Cows

Erin Bell, Animal Welfare Program

Signs of laminitis, such as sole hemorrhaging or sole ulcers, can be seen in the hooves of dairy cattle following trimming. Below are some pictures showing examples of some laminitic lesions.

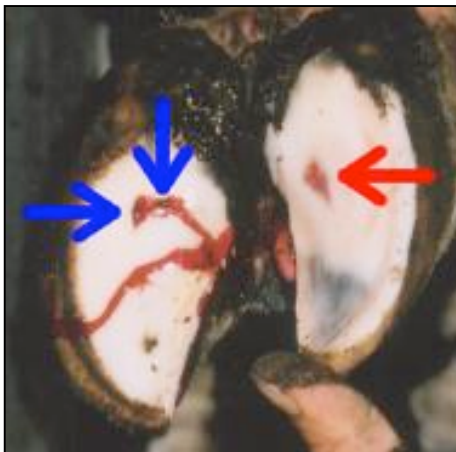

This is a healthy hoof with just a slight yellowish discoloration on the right claw, indicating the preliminary stage of laminitis in this one area.



This cow has laminitis in her left claw.

Two sole ulcers (**blue arrows**) and some slight hemorrhaging (**red arrow**) are visible.



This cow is also suffering from laminitis.

There is a severe hemorrhage (**red arrow**) on the right claw, and the left claw contains two sole ulcers (**blue arrows**).